


**The Case Of:
The Visiting Pregnant Lady**
November 6, 2013

KELLEN SIKORA, MD
UNIVERSITY OF CONNECTICUT

Patient Presentation

A 32 yo G3P2002 at 29.1 weeks gestation with sudden and severe abdominal pain while visiting a family member in the ED; patient alert and oriented

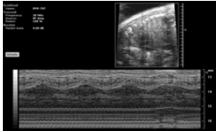
- ROS
 - No Leakage of fluid
 - no vaginal bleeding
 - unknown if contracting
 - unknown fetal movement
- IV placed
- Vitals: HR 100, BP 90/60



QUESTIONS???

Initial Fetal Monitoring

- Bedside ultrasound showed fetal heart rate in the 60s
 - > OB emergently notified
- OB repeated ultrasound, confirming fetal rate in the 60s
 - > Patient taken immediately to Labor and Delivery operating room




QUESTIONS???

Patient History

No records available from OSH, per patient no prenatal complications, no history of substance abuse, and no recent trauma

PObhx: 2 Term cesarean sections
PMhx: Denied



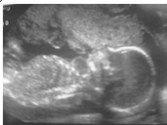
QUESTIONS???

Further Fetal Monitoring

Arrival • **Electronic Fetal Monitoring:** 80s, steadily increasing, min variability

5 Min • **Ultrasound:** vertex, adequate AFI, anterior placenta, no retroplacental hematoma


12 Min • **Electronic Fetal Monitoring:** increasing fetal heart rate to 180s over 12 minutes, minimal variability, no accelerations



QUESTIONS???

Maternal Evaluation

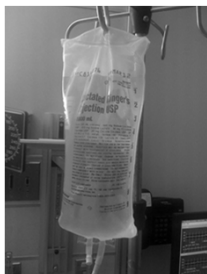<p>Vitals: T 98.3, HR 93, BP 76/63, RR 22, 100%RA</p>	<p>General: Writhing, uncomfortable</p>
<p>Abdomen: Gravid, +tender to palpation diffusely, +guarding, +rebound</p>	<p>Sterile Vaginal Exam: Closed/thick/posterior no blood</p>



QUESTIONS???

Next Steps

- Second IV placed, CBC, UA, Type and Screen sent
- Foley catheter placed
- IV fluid bolus started
- Fetal Monitoring: baseline 160, mod variability, no accelerations, no decelerations
- Stat General Surgery Consult placed



QUESTIONS???

Significant Lab Values

- Hemoglobin 9.6g/dL, Hematocrit 28.2%
- Platelets 202,000
- Normal UA



QUESTIONS???

Clinically

- Patient became very agitated
- BP: 60/30
- Fetal Monitoring: precipitous drop to 70



QUESTIONS???



Surgery

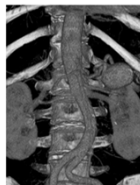
- Stat midline vertical with classical cesarean section performed
- Massive hemoperitoneum noted
- Massive transfusion protocol initiated
- Uterus, ovaries, and fallopian tubes normal
- General surgery residents arrived, extended the incision, and packed the abdomen



QUESTIONS???

Surgical Discovery

- Bleeding noted from the lesser sac
- Splenectomy performed
- Vascular surgery consulted, 1.5cmx1cmx1cm splenic artery aneurysm removed
- EBL for entire case was 10Liters
- Pt received 12U PRBCs, 9U FFP, 6 packs of platelets
- Patient brought to the ICU intubated with an open abdomen



QUESTIONS???

Outcome

Patient

- Post operative Hematocrit: 30.3%
- Discharged on post operative day 10 with a PICC line for a small pancreatic leak

Baby

- Apgars: 1 @ 1 min, 2 @ 5 min
- Birth weight: 1,476g
- Birth pH: 6.9
- Discharged home on DOL 70

